

MORPHOMETRY OF GASTRIC WALL LAYERS UNDER THE INFLUENCE OF PALM OIL

Ro‘zibek T. Tolmasov ¹, Utkir M. Mirsharapov ²

¹ Independent Researcher, Assistant of the Department of Human Anatomy and OSTA
Tashkent Medical Academy, Tashkent, Uzbekistan
E-mail: tolmasovrozbek@gmail.com

² Doctor of Medical Sciences, Professor of the Department of Human Anatomy and
OSTA, Tashkent Medical Academy, Tashkent, Uzbekistan

ABSTRACT

Obesity is currently one of the most common chronic diseases in the world. It should be noted that nutrition accounts for 97% of all forms of obesity. This is largely due to changes in daily nutrition and lifestyle. The relevance of this problem is due to the fact that obesity is the main factor and is associated with metabolic diseases. It significantly increases the risk of developing many diseases and pathological processes

To develop prevention of gastric diseases and increase the possibility of reducing disease complications by comparative morphometric analysis of the structure of the mucous, submucosal, muscular and serous membranes of the gastric wall of rats fed palm oil, comparative analysis of the density of mucous glands, and evaluation and comparison of their morpho-functional changes under experimental conditions.

Key words: Rats, NanoZoomer, stomach, Palm oil, muscle, morphometry, postnatal ontogenesis, micrograph.

INTRODUCTION

In our country, comprehensive measures are being implemented to develop the medical field, in particular, to reduce the incidence of diseases of the functional and organic activity of the digestive organs and their complications, as well as to improve and prevent the treatment of diseases, and certain results are being achieved.

Based on our scientific research, comparative morphometric analysis of the structure of the mucous, submucosal, muscular and serous layers of the stomach

wall layers of rats fed palm oil, comparative analysis of the density of the mucous glands, and their morphological and functional changes in experimental conditions using laboratory tests and comparisons allow us to develop statistical analysis indicators of the stomach wall layers [2,3,4,6,8,9,10,11,14,17,18].

Research objective. Determination of the layers of the stomach wall and study of morphometric parameters of white male rats exposed to palm oil during experimental postnatal ontogenesis.

Materials and methodology. The study material was the stomachs of 150 white male laboratory rats of different ages: 21, 60, 90, 120, 150, 180 days old, with a body weight of 48 grams to 220 grams, divided into 2 groups (control and experimental). The experimental animals were kept under normal laboratory diet conditions. Their control group continued to be fed a daily constant diet. The second experimental group of white rats was additionally fed 1.7 g/kg of Palm oil (Premium Carotino) [1,5,7,12,13,15,16] during daytime feeding, in addition to the special diet given to the rats in the laboratory, by oral gavage.

The morphometric examination of the mucous, submucosal, muscular and outer serous layers of the stomach wall of the studied white male laboratory rats was carried out using the G.G. Avtandilov method and the NanoZoomer (REF C13140- 21.S/N000198/HAMAMATSU PHOTONICS /431-3196 JAPAN) Hamamatsu (QuPath-0.4.0, NanoZoomer Digital Pathology Image) morphometric computer program. The obtained data were calculated in the statistical section of Microsoft Excel 2010 as the arithmetic mean M , the average error of the relative sizes m and the coefficient of precision t . Micrographs of histological preparations were taken using a microscope with an OD400 camera on the CX40 model.

Results and discussion. The stomach (ventricle) of rats is located in the left part of the abdominal cavity, opposite the last thoracic and first lumbar vertebrae. The stomach of rats is a crescent-shaped sac, weighing from 3.9 grams to 9.5 grams. The stomach tissue of rats is approximately 1.8% of the total body weight. In this work, we will focus on the morphometry of the stomach walls of white male laboratory rats studied.

In the experimental part of our work, the following data were obtained when 21-day-old control group rats were studied. The weight of 21-day-old control group rats is 48-55 grams, an average of 51.5 ± 0.14 g.

The gastric wall thickness of 21-day-old male white rats in the control group was 270.81 ± 23.5 μm , the submucosa thickness was 135.65 ± 23.4 μm , the muscularis and serosa layers were 202.0 ± 15.5 μm , and the total gastric wall thickness was 0.61 ± 0.06 mm. The average distribution of the density of the mucous glands was 6.20 ± 0.36 mm² (Table 1).

The weight of 60-day-old male white rats in the control group ranged from 70 g to 82 g, with an average of 75.6 ± 2.08 g. The thickness of the gastric wall mucosa of 60-day-old rats in the control group was 542.30 ± 50.2 μm , the thickness of the submucosa was 280.64 ± 50.0 μm , the average thickness of the muscular and serous layers was 275.0 ± 28.0 μm , and the total thickness of the gastric wall was 1.10 ± 0.13 mm. The average distribution of the density of the mucous glands was 10.0 ± 0.60 mm^2 (Table 1).

The weight of 90-day-old male white rats in the control group ranged from 100 g to 120 g, with an average of 110.2 ± 3.08 g. The thickness of the gastric mucosa of the 90-day-old rats in the control group was 701.81 ± 15.0 μm , the thickness of the submucosa was 416.71 ± 43.5 μm , the average thickness of the muscular and serous layers was 280.2 ± 12.1 μm , and the total thickness of the gastric wall was 1.40 ± 0.07 mm. The average distribution of the density of the mucous glands was 13.8 ± 0.32 mm^2 (Table 1).

The weight of the 120-day-old male white rats in the control group ranged from 130 g to 150 g, with an average of 141.6 ± 2.23 g. The thickness of the gastric mucosa of the 120-day-old rats in the control group was 782.22 ± 23.1 μm , the thickness of the submucosa was 440.66 ± 50.0 μm , the thickness of the muscular and serous layers was 306.5 ± 30.0 μm , and the total thickness of the gastric wall was 1.53 ± 0.10 mm. The average distribution of the density of the mucous glands was 15.4 ± 0.21 mm^2 (Table 1).

The weight of the 150-day-old male white rats in the control group ranged from 165 g to 186 g, with an average of 175.5 ± 4.34 g. The thickness of the gastric mucosa of the 150-day-old rats in the control group was 810.41 ± 64.0 μm , the thickness of the submucosa was 461.20 ± 35.2 μm , the average thickness of the muscular and serous layers was 328.3 ± 61.0 μm , and the total thickness of the gastric wall was 1.60 ± 0.16 mm. The average distribution of the density of the mucous glands was 16.5 ± 0.15 mm^2 (Table 1).

The weight of the 180-day-old male white rats in the control group ranged from 200 g to 220 g, with an average of 211.6 ± 3.54 g. The thickness of the gastric mucosa of the 180-day-old rats in the control group was 835.72 ± 75.0 μm , the thickness of the submucosa was 478.20 ± 24.1 μm , the thickness of the muscularis and serosa layers was 344.1 ± 80.3 μm , and the total thickness of the gastric wall was 1.66 ± 0.18 mm on average. The average distribution of the density of the mucous glands was 17.1 ± 0.12 mm^2 (Table 1).

Table-1**Morphometric parameters of the stomach wall layers of control group rats of different ages (M±m);**

Rats age	Mucosal layer (µm)	Submucosa (µm)	Muscular and serous layers (µm)	Total stomach wall thickness (mm)	Gland density mm ²
21 days	270,81±23,5	135,65±23,4	202,0±15,5	0,61 ± 0,06	6,20 ± 0,36
60 days	542,30 ±50,2	280,64±50,0	275,0±28,0	1,10 ± 0,13	10,0 ± 0,60
90 days	701,81 ±15,0	416,71±43,5	280,2±12,1	1,40 ± 0,07	13,8 ± 0,32
120 days	782,22 ±23,1	440,66±50,0	306,5±30,0	1,53 ± 0,10	15,4 ± 0,21
150 days	810,41 ±64,0	461,20±35,2	328,3±61,0	1,60 ± 0,16	16,5 ± 0,15
180 days	835,72 ±75,0	478,20±24,1*	344,1±80,3	1,66 ± 0,18*	17,1 ± 0,12

The following data were obtained when the 21-day experimental group of male white rats was studied. The weight of 21-day rats after 30 days of palm oil consumption was 73-80 g, an average of 76.5 ± 1.2 g. The thickness of the gastric mucosa of the 21-day rats in the experimental group was 300.90 ± 26.1 µm, the thickness of the submucosa was 159.60 ± 27.5 µm, the average thickness of the muscular and serous layers was 246.3 ± 19.0 µm, and the total thickness of the gastric wall was 0.71 ± 0.07 mm. The density of the mucous glands was 7.30 ± 0.42 mm² on average, and the gastric mucosa of the control group rats changed by 21% from the density of the glands (Table 2).

The morphometric parameters of the stomach wall of 60-day-old male white rats were as follows: the weight of 60-day-old rats after 30 days of palm oil consumption was 100-112 g, with an average of 107 ± 2.5 g. The thickness of the gastric mucosa of the 60-day-old rats in the experimental group was 616.25 ± 57.0 µm, the thickness of the submucosa was 342.24 ± 60.9 µm, the average thickness of the muscular and serous layers was 343.7 ± 35.0 µm, and the total thickness of the gastric wall was 1.30 ± 0.15 mm. The density of the mucous glands was 12.8 ± 0.77 mm² on average, and the gastric mucosa of the control group rats changed by 21% from the gland density (Table 2).

When the 90-day experimental group of male white rats was studied, the following data were obtained from the morphometric indicators of the stomach wall.

After 30 days of palm oil consumption, the weight of 90-day rats was 135-155 g, on average 146 ± 1.7 g. The thickness of the gastric mucosa of the 90-day

rats in the experimental group was $825.66 \pm 17.6 \mu\text{m}$, the thickness of the submucosal layer was $520.88 \pm 54.4 \mu\text{m}$, the average thickness of the muscular and serous layers was $318.4 \pm 14.7 \mu\text{m}$, and the total thickness of the gastric wall was $1.40 \pm 0.08 \text{ mm}$. The density of the mucous glands was on average $17.3 \pm 0.40 \text{ mm}^2$, and the gastric mucosa of the control group rats changed by 21% from the gland density (Table 2).

When the 120-day-old male white rats were studied, the following data were obtained from the morphometric parameters of the stomach wall.

After 30 days of palm oil consumption, the weight of the 120-day-old rats was 168-188 g, with an average of $178 \pm 1.4 \text{ g}$. The thickness of the gastric wall mucosa of 120-day-old rats in the experimental group was $920.26 \pm 27.2 \mu\text{m}$, the thickness of the submucosa was $579.81 \pm 65.8 \mu\text{m}$, the average thickness of the muscular and serous layers was $383.1 \pm 37.5 \mu\text{m}$, and the total thickness of the gastric wall was $1.53 \pm 0.12 \text{ mm}$. The density of the mucous glands was $19.7 \pm 0.27 \text{ mm}^2$ on average, and the gastric mucosa of the control group rats changed by 21% from the gland density (Table 2).

When the obtained 150-day-old male white rats were studied, the following data were obtained from the morphometric parameters of the gastric wall.

After 30 days of palm oil consumption, the weight of 150-day-old rats was 205-226 g, with an average of $215.5 \pm 1.1 \text{ g}$. The thickness of the gastric mucosa of the 150-day-old rats in the experimental group was $920.92 \pm 72.7 \mu\text{m}$, the thickness of the submucosa was $576.50 \pm 44.0 \mu\text{m}$, the average thickness of the muscular and serous layers was $400.4 \pm 74.4 \mu\text{m}$, and the total thickness of the gastric wall was $1.60 \pm 0.19 \text{ mm}$. The density of the mucous glands was $20.6 \pm 0.19 \text{ mm}^2$ on average, and the gastric mucosa of the control group rats changed by 20% from the density of the glands (Table 2).

The following data were obtained from the morphometric parameters of the stomach wall of the 180-day experimental group of male white rats.

The weight of 180-day rats after 30 days of palm oil consumption was 244-264 g, an average of $255 \pm 1.6 \text{ g}$. The thickness of the gastric wall of the 180-day rats in the experimental group was $960.60 \pm 86.2 \mu\text{m}$, the thickness of the submucosal layer was $562.59 \pm 28.3 \mu\text{m}$, the average thickness of the muscular and serous layers was $409.6 \pm 95.6 \mu\text{m}$, and the total thickness of the gastric wall was $1.66 \pm 0.21 \text{ mm}$. The density of the mucous glands averaged $21.6 \pm 0.15 \text{ mm}^2$, and the gastric mucosa of the control group rats changed by 21% from the gland density (Table 2).

Table-2

Morphometric parameters of the stomach wall layers of experimental groups of rats of different ages (M±m);

Rats age	Mucosal layer (µm)	Submucosa (µm)	Muscular and serous layers (µm)	Total stomach wall thickness (mm)	Gland density mm ²
21 days	300,90±26,1	159,60±27,5	246,3±19,0	0,71 ± 0,07	7,30 ± 0,42
60 days	616,25 ±57,0	342,24±60,9	343,7±35,0	1,30 ± 0,15	12,8 ± 0,77
90 days	825,66 ±17,6	520,88±54,4	318,4±14,7	1,40 ± 0,08	17,3 ± 0,40
120 days	920,26 ±27,2	579,81±65,8	383,1±37,5	1,53 ± 0,12	19,7 ± 0,27
150 days	920,92 ±72,7	576,50±44,0	400,4±74,4	1,60 ± 0,19	20,6 ± 0,19
180 days	960,60 ±86,2*	562,59±28,3	409,6±95,6*	1,66 ± 0,21	21,6 ± 0,15

Note:* - P<0.05 is significant compared to the control group.

When comparing the morphometric parameters of the stomach wall layers in the experimental group at 21, 60, 90, 120, 150, and 180 days of age with the stomach wall layers of the control group rats, the differences were as follows:

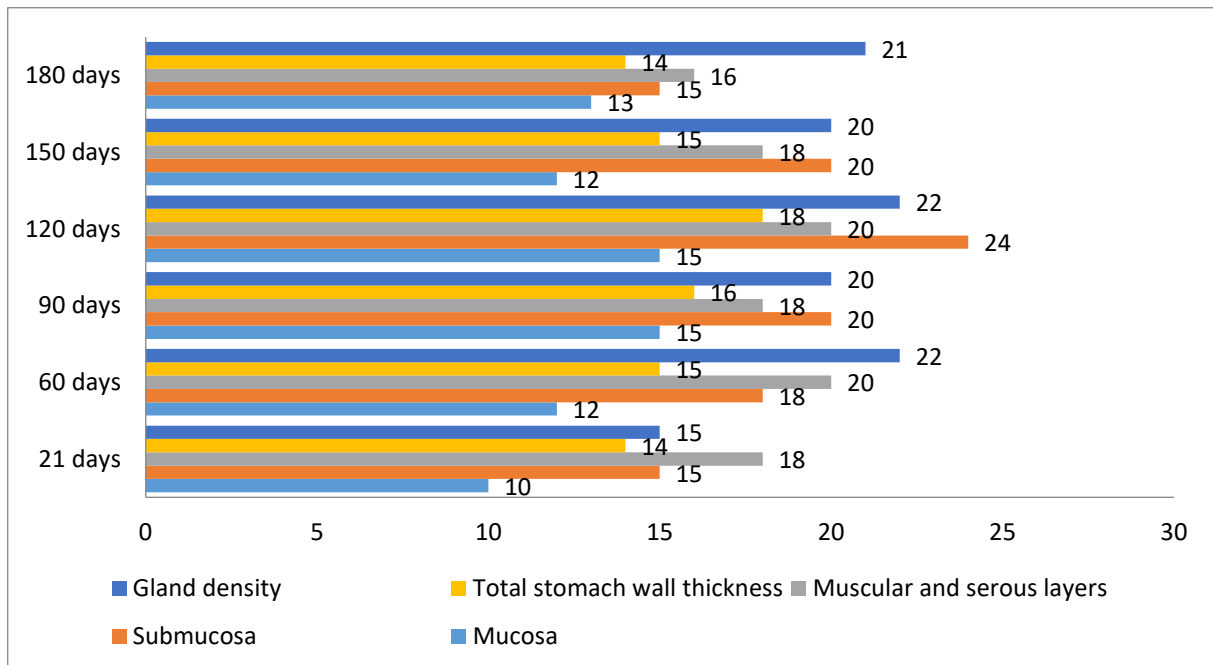


Figure 1. Percentage (%) increase in morphometric parameters of the stomach wall layers of the experimental group of rats compared to the control group of different ages.

In the 21-day-old experimental animals studied, it was found that the total thickness of the stomach wall increased by 14% compared to the 21-day-old control group. In this case, the mucosa thickened by 10%, the submucosa by 15%, the muscular and serous layers by 18%, and the greatest increase was observed in the submucosa and the muscular-serous layers. The density of the mucous glands increased by 15% (Figure 1).

In the 60-day-old experimental animals studied, it was found that the total thickness of the stomach wall increased by 15% compared to the 60-day-old control group. In this case, the mucosa thickened by 12%, the submucosa by 18%, the muscular and serous layers by 20%, and the greatest increase was observed in the muscular-serous layers. The density of the mucous glands increased by 22% (Figure 1).

In the 90-day-old experimental animals studied, it was found that the total thickness of the stomach wall increased by 16% compared to the 90-day-old control group. In this case, the mucosa thickened by 15%, the submucosa by 20%, the muscular and serous layers by 18%, and the greatest increase was observed in the submucosa. The density of the mucous glands increased by 20% (Figure 1).

In the 120-day-old experimental animals studied, it was found that the total thickness of the stomach wall increased by 18% compared to the 120-day-old control group. In this case, the mucosa thickened by 15%, the submucosa by 24%, the muscular and serous layers by 20%, and the greatest increase was observed in the submucosa. The density of the mucous glands increased by 22% (Figure 1).

In the 150-day-old experimental animals studied, it was found that the total thickness of the stomach wall increased by 15% compared to the 150-day-old control group. In this case, the mucosa thickened by 12%, the submucosa by 20%, the muscular and serous layers by 18%, and the greatest increase was observed in the submucosa. The density of the mucous glands increased by 20% (Figure 1).

In the 180-day-old experimental animals studied, it was found that the total thickness of the stomach wall increased by 14% compared to the 180-day-old control group. In this case, the mucosa thickened by 13%, the submucosa by 15%, the muscular and serous layers by 16%, and the greatest increase was observed in the muscular-serous layer. The density of the mucous glands increased by 21% (Figure 1).

Conclusion. In the experimental postnatal ontogenesis we are studying, the following data were obtained based on the morphometric parameters of the stomach wall layers of white male rats exposed to palm oil.

Morphometric changes in the stomach wall layers of rats in the control group at 21, 60, 90, 120, 150, 180 days were studied. It was found that the total thickness

of the stomach wall of the experimental group rats changed by 14% compared to the control group at 21 days, the total thickness of the stomach wall of the rats at 60 days was 15%, the total thickness of the stomach wall of the rats at 90 days was 16%, the total thickness of the stomach wall of the rats at 120 days was 18%, the total thickness of the stomach wall of the rats at 150 days was 15%, and the total thickness of the stomach wall of the rats at 180 days was 14%.

REFERENCES

1. Bibik E. Yu. E. Yu. Bibik, D. V. Romanenko, N. V. Reshetilo [i dr.] // Ukrainian morphological almanac. - 2014. - T. 12. – No. 3. – S. 65-67.
2. Buvabekov M. M. Morfologicheskie osobennosti formirovaniyaslizistoy obolochki fundalnogo otdela jeludka krysa v postnatalnom ontogeneze / M. M. Buvabekov, A. Yu. Yuldashev, R. R. Rakhmanov [i dr.] // Medicine of Kyrgyzstan. – 2019. – No. 1. – S. 31-36.
3. Bittar NM, Zulian JG, Ogias D, Gama P. Ghrelin and GHS-R in the rat gastric mucosa: Are they involved in regulation of growth during early weaning? Nutrition. 2016 Jan;32(1):101-7.
4. Gayvoronskaya, Yu. V. Strukturno-funksionalnoe sostoyanie nadpochechnyx zhelet u belyx krysa razlichnogo vozrasta pri izbytochnom upotreblenii palmovogo masla / Yu. V. Gayvoronskaya // Bulletin of the medical internet conference. - 2018. - T. 8. – No. 7. – S. 274-276.
5. Ismailova, K. R. Vliyanie izbytochnogo potrebleniya palmovogo masla na ultrastrukturu biominerala dentina na razlichnykh etatax postnatalnogo ontogeneza / K. R. Ismailova // Ukrainsky morfologichesky almanac named after professor V.G. Koveshnikova. - 2017. - T. 15. – No. 2. – S. 14-19.
6. Kamoldinova, R. A. Osobennosti formirovaniya slizistoy obolochki jeludka krysa v postnatalnom ontogeneze / R. A. Kamoldinova, R. R. Rakhmanov, Kh. Z. Ibragimova // Re-health Journal. – 2020. – No. 2(6). - S. 65-71.
7. Lyashchuk, A. V. Morfofunksionalnoe sostoyanie proximalnogo epiphyzarnogo khryashcha bolshebertsovykh kostey pri izbytochnom sodержanii palmovogo masla v ratione u belyx krysa razlichnogo vozrasta / A. V. Lyashchuk // Ukrainian morphological almanac. - 2015. - T. 13. – No. 3-4. - S. 81-85.
8. Mirzoyan E., Chekunkov V.V., Davidenko V.N., Markvo L.I. Histological manifestation of early differentiation of smooth muscle cells of stenki kishechnoy trubki germinal rat in prenatal period and postnatal histogenesis in stenke stomach rat//Mejdunarodnyi studencheskiy nauchnyi vestnik. - 2015. - No. 2-2. - S. 144.

9. Matsukura N., Shiota A., Asano G. Anatomy, histology, ultrastructure, stomach, rat //Digestive system. – Berlin, Heidelberg : Springer Berlin Heidelberg, 1985. – S. 281-288.
10. Nickel VV, Efremova VP. Age changes in connective tissue structures of the stomach. // Adv Gerontol. 2017;30(5):665-670. Russian. PMID: 29322731.
11. Petrenko V.M. Form and topography of the stomach of white mice // Uspekhi sovremennogo estestvoznaniya. – 2012. – No. 4. – S. 27-29.
12. Rustamov B. B., Ermatov N. J. Pishchevaya tsennost krasnogo palmovogo masla //Meditsinskie novosti. – 2016. – no. 12 (267). - S. 65-67.
13. Simakova I. V. Intensivnost patologicheskikh izmeneniy v organizmeivotnykh v zavisimosti ot stepi okisleniya palmovogo masla / I. V. Simakova, V. V. Zakrevsky, R. L. Perkel, M. N. Kutkina // Voprosy pitaniya. - 2016. - T. 85. – No. S2. - S. 36.
14. Cheraneva M.V. Morphological parameters of the mucous membrane of the stomach of a sterile white rat, used in experiments//Uchenye zapiski Kazanskoy gosudarstvennoy akademii veterinarnoy meditsiny im. N.E. Baumana. - 2011. - T. 208, No. 4. - S. 407-412.
15. Shaikhova G.I., Ermatov N.J., Rustamov B.B. Hygienic assessment of nutritional and biological value of red palm oil //Monograph. - 2022.
16. Ermatov, N. J. Izuchenie morfologicheskogo sostava krovi u eksperimentalnykh zivotnykh pri izuchenii toksicheskikh svoystv krasnogo palmovogo masla "premium Caratino" / N. J. Ermatov, B. B. Rustamov // World science: problems and innovations : sbornik statey XVI Mejdunarodnoy nauchno-prakticheskoy konferentsii : v 3 ch., Penza, December 25, 2017. – Penza: "Nauka i Prosveshchenie" (IP Gulyaev G.Yu.), 2017. – S. 261-263.
17. Yuldashev A. Yu. Morfologicheskie osobennosti formirovaniya slizistoy obolochki fundalnogo otdela zhudka krys v postnatalnom ontogeneze / A. Yu. Yuldashev, S. Z. Yuldasheva, M. X. Rakhmatova [i dr.] // Biology of sweet medicine. - 2014. - T. 10. – No. 4-2(47). - S. 214-219.
18. Zhu L., Wang J.L. Sexual dimorphism in histological structure of normal rat stomach //Int. J. Morphol., Temuco. - 2016. - T. 34. – no. 4. – S. 1461-1464.